
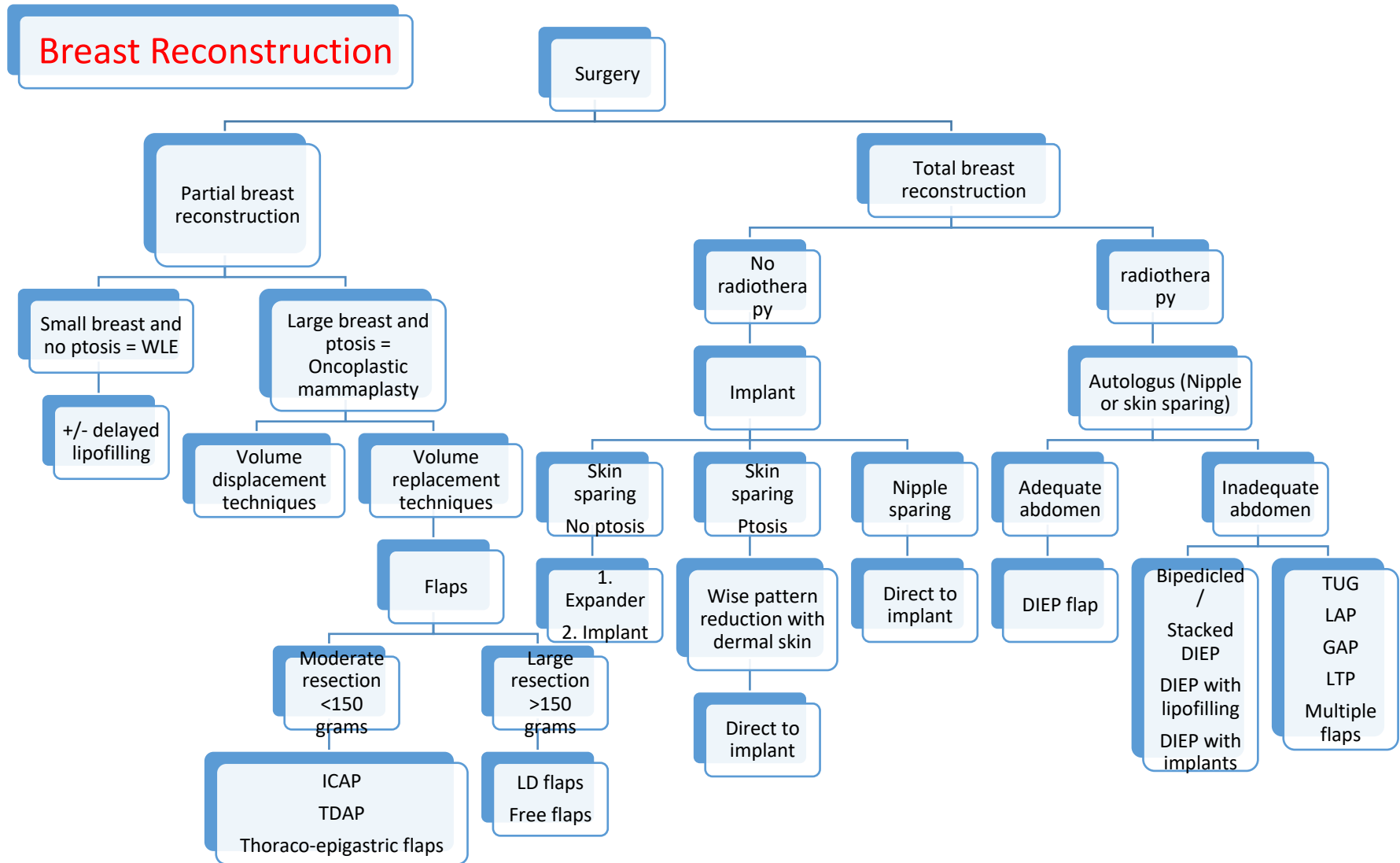


# **NCG Plastic and Reconstructive Surgery Guidelines 2024**



## INDEX

No	Modalities	Page Number
1	Breast recon algorithm	3
2	Buccal Mucosa	5
3	Chest and abdominal wall	7
4	Lower limb reconstruction	11
5	Mandible reconstruction	13
6	Maxilla reconstruction	16
7	Pharyngeal reconstruction	18
8	Skull base	20
9	Tongue reconstruction	22
10	Upper Limb	24



Legends-

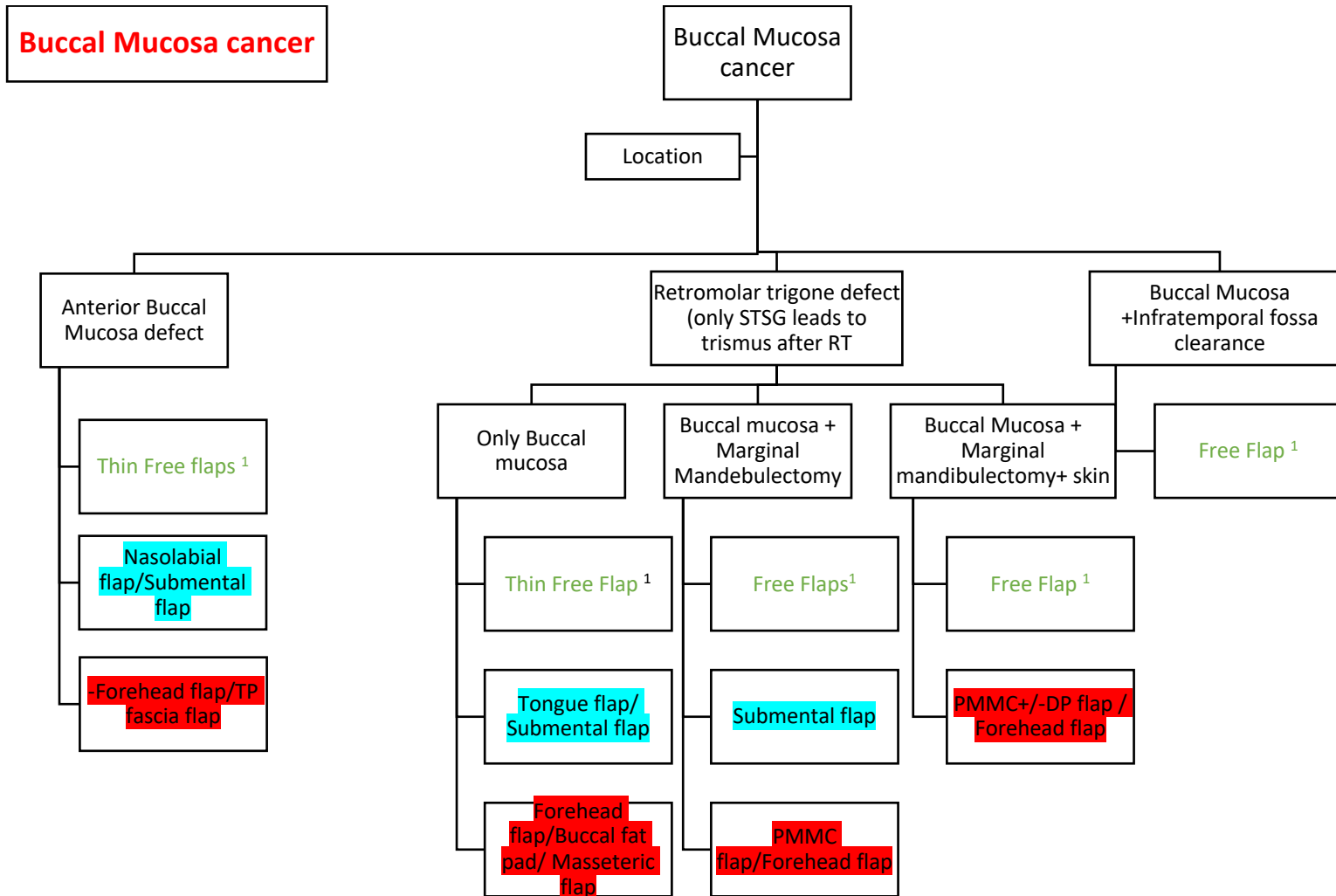
# National Cancer Grid

## Plastic & Reconstruction Guidelines 2024

---

ICAP- Inter-coastal artery perforator  
TDAP- Thoracodorsal artery perforator  
LD- Latissimus dorsi  
DIEP- Deep inferior epigastric artery perforator  
TUG- Transverse upper gracilis  
LAP- Lumbar artery perforator  
GAP- Gluteal artery perforator  
LTP- Lateral thoracic perforator

- Breast Reconstruction

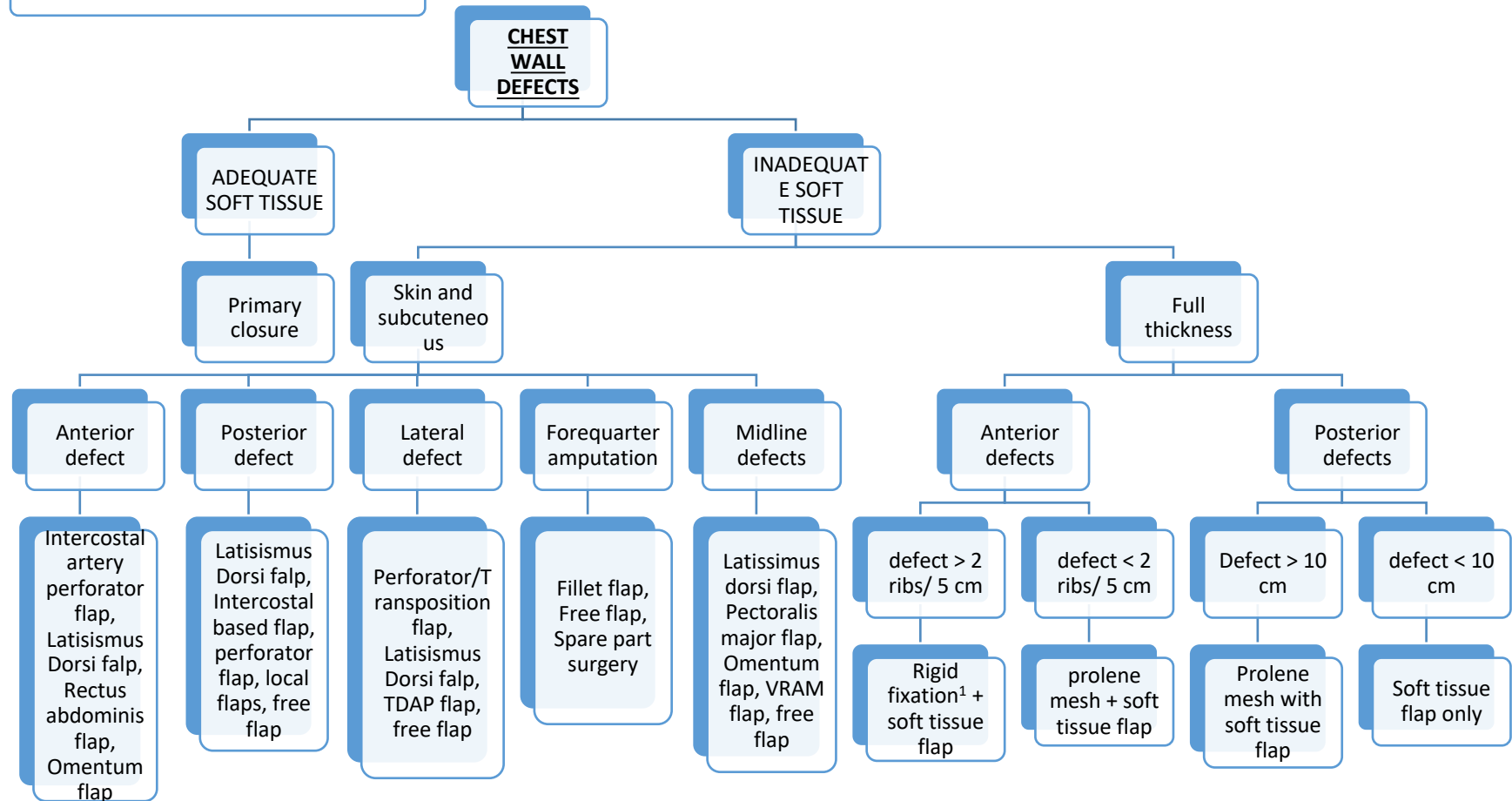


- Green signifies best/preferred option, Blue signifies- resource based options, Red signifies salvage options
- 1- FRAFF/FALT/TDAP/MSAP – depending on thickness and pliability of donor site. Flap should provide adequate bulk

## References

1. Chin-Yen Chien ,Chung-Feng Hwang, Hui-Ching Chuang , Seng –Feng Jeng, Chih-Ying Su .Comparision of radial forearm free flap , pedicled buccal fat pad flap and split –thickness skin graft in reconstruction of buccal mucosa defect . *Oral Oncol.*2005Aug;41(7):694-7 .
2. Schonauer F, Di Martino A, Nele G, Santoro M, Dell'Aversana Orabona G, Califano L. Submental flap as an alternative to microsurgical flap in intraoral post-oncological reconstruction in the elderly. *Int J Surg.* 2016;33 Suppl 1:S51-S56.
3. Fairouz Chouikh The Buccal Fat Pad Flap .*Oral Maxillofacial Surg Clin N Am* 33 (2021) 177–184 .
4. Vijay Kumar, Sourabh Mukherjee, Naseem Akhtar , Siv Rajan , Arun Chaturvedi, Sameer Gupta , Puneet Prakash, Satyabrata Das. Tongue flap reconstruction in carcinoma of oral cavity :An institutional experience *J. Maxillofac. Oral Surg.* (july -Sept 2019) 18(3);428-43 .
5. Shao-Liang Chen , Chien –Chih Yu, Meing-Chang, Shou-Chen Deng Yueng-Shiang and Tim-Mo Chen .Medial sural artery perforator flap for intraoral reconstruction following cancer ablation . *Ann Plast Surg* 2008;61:274-279)
6. D.S. Soutar, L.R. Scheker, N.S.B. Yanner and I.A. McGregor .The radial forearm flap : A versatile method for intra-oral reconstruction *British journal of plastic surgery* (1983) 36,1-8
7. Roberto Squaquara, Karen F .Kim Evans, Stefano Spaniodi Spilimbergo, and Samir Mardini .Intraoral reconstruction using local and regional flaps ; *Semin Plat Surg* 2010;24:198-211
8. Hemant Nemade , Naren Bollineni Sagar Mortha , G Jonathan, Sravan Kumar , LMCS Rao, Subramanyeshwar Rao .Marginal mandibulectomy defect reconstruction with pectoralis major myocutaneous (PMMC) flap in cases of carcinoma buccal mucosa ; Experience from tertiary cancer institute *Indian Journal of Surgical Oncology* (September 2020 ) 11(3):482-485
9. Song M, Chen Fj, Guo ZM , Zhang Q , Yang AK : Application of various flaps to intraoral recontruction of buccal defect after resection of buccal mucosa carcinoma *Ai Zheng* 2009, 28 ;663-667
10. Arik Zaretski , Fu –Chan Wei and Christopher Glenn Wallace . Anterolateral thigh perforator flaps in head and neck reconstruction ; *Semin Plast Surg* 2006;20:2;64-72 .

## CHEST WALL DEFECTS



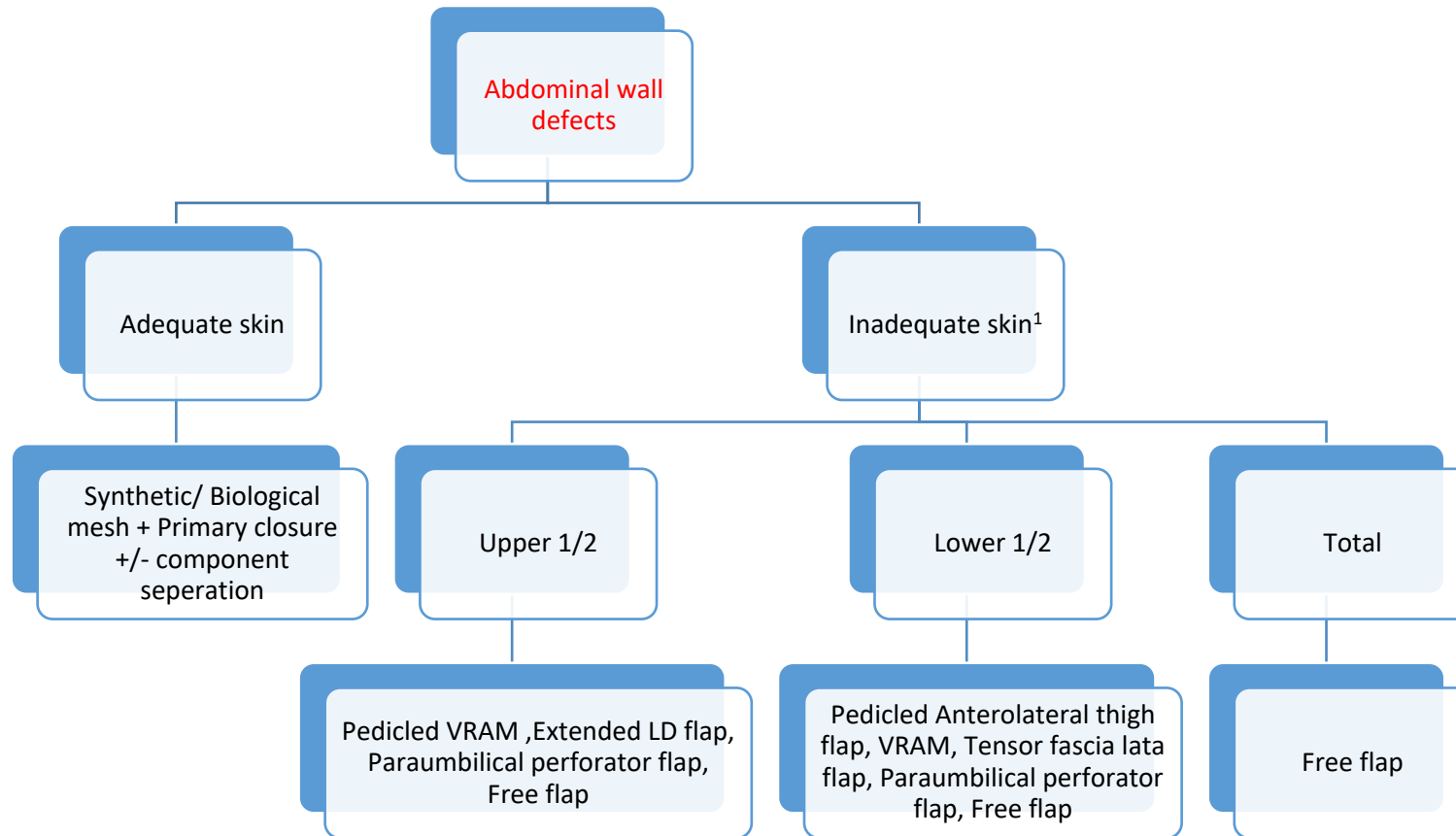
- Options for rigid fixation- Mesh cement sandwich, titanium mesh, titanium plate, autograft, allograft

2. Split thickness skin graft is an option if the bed is graftable and adjuvant radiation is not required

### REFERENCES –

1. Cohen M, Ramasastry SS. Reconstruction of complex chest wall defects. *The American journal of surgery*. 1996 Jul 1;172(1):35-40.
2. Chang RR, Mehrara BJ, Hu QY, Disa JJ, Cordeiro PG. Reconstruction of complex oncologic chest wall defects: a 10-year experience. *Annals of plastic surgery*. 2004 May 1;52(5):471-9.
3. Sanna S, Brandolini J, Pardolesi A, Argnani D, Mengozzi M, Dell'Amore A, Solli P. Materials and techniques in chest wall reconstruction: a review. *Journal of visualized surgery*. 2017;3.
4. Mathes SJ. Chest wall reconstruction. *Clinics in plastic surgery*. 1995 Jan 1;22(1):187-98.
5. Di Candia M, Wells FC, Malata CM. Anterolateral thigh free flap for complex composite central chest wall defect reconstruction with extrathoracic microvascular anastomoses. *Plastic and Reconstructive Surgery*. 2010 Nov 1;126(5):1581-8.
6. Dingman RO, Argenta LC. Reconstruction of the chest wall. *The Annals of Thoracic Surgery*. 1981 Aug 1;32(2):202-8.
7. Volpe CM, Peterson S, Doerr RJ, Karakousis CP. Forequarter amputation with fasciocutaneous deltoid flap reconstruction for malignant tumors of the upper extremity. *Annals of Surgical Oncology*. 1997 Jun;4(4):298-302.
8. Tukiainen E. Chest wall reconstruction after oncological resections. *Scandinavian Journal of Surgery*. 2013 Mar;102(1):9-13.
9. Matros E, Disa JJ. Uncommon flaps for chest wall reconstruction. *Semin Plast Surg*. 2011 Feb;25(1):55-9. doi: 10.1055/s-0031-1275171. PMID: 22294943; PMCID: PMC3140228.
10. Ayyala HS, Mohamed OM, Therattil PJ, Lee ES, Keith JD. The forearm fillet flap: 'spare parts' reconstruction for forequarter amputations. *Case Reports PlastSurg Hand Surg*. 2019 Sep 20;6(1):95-98. doi: 10.1080/23320885.2019.1666718. PMID: 31595221; PMCID: PMC6764346.
11. Sanna S, Brandolini J, Pardolesi A, Argnani D, Mengozzi M, Dell'Amore A, Solli P. Materials and techniques in chest wall reconstruction: a review. *J Vis Surg*. 2017 Jul 26;3:95. doi: 10.21037/jovs.2017.06.10. PMID: 29078657; PMCID: PMC5638032.





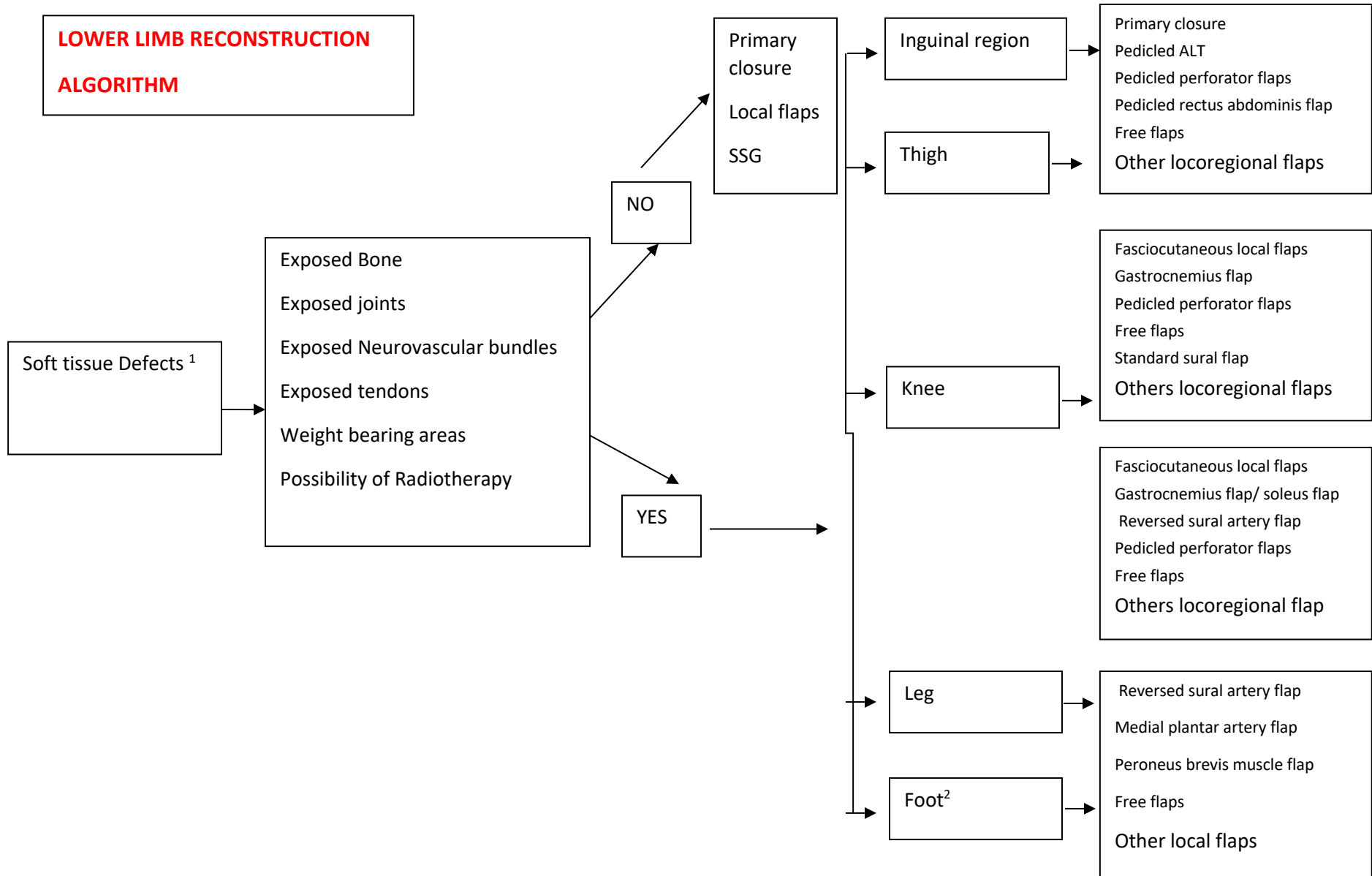
1. Biological or synthetic mesh is used for rectus defects.

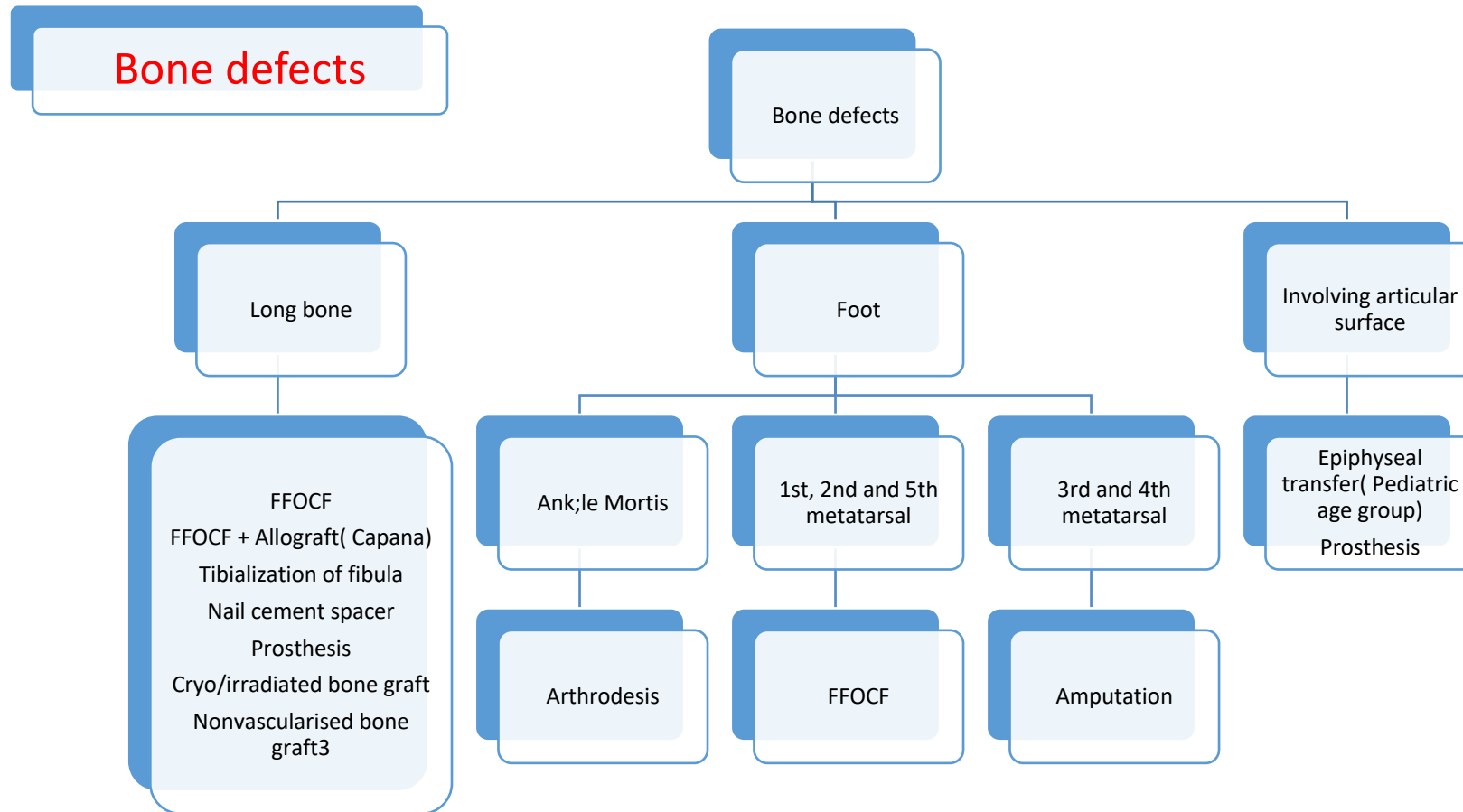
Legends-

TDAP flap- thoracodorsal artery perforator flap  
VRAM flap- Vertical rectus abdominis muscle flap  
LD- latissimus dorsi flap

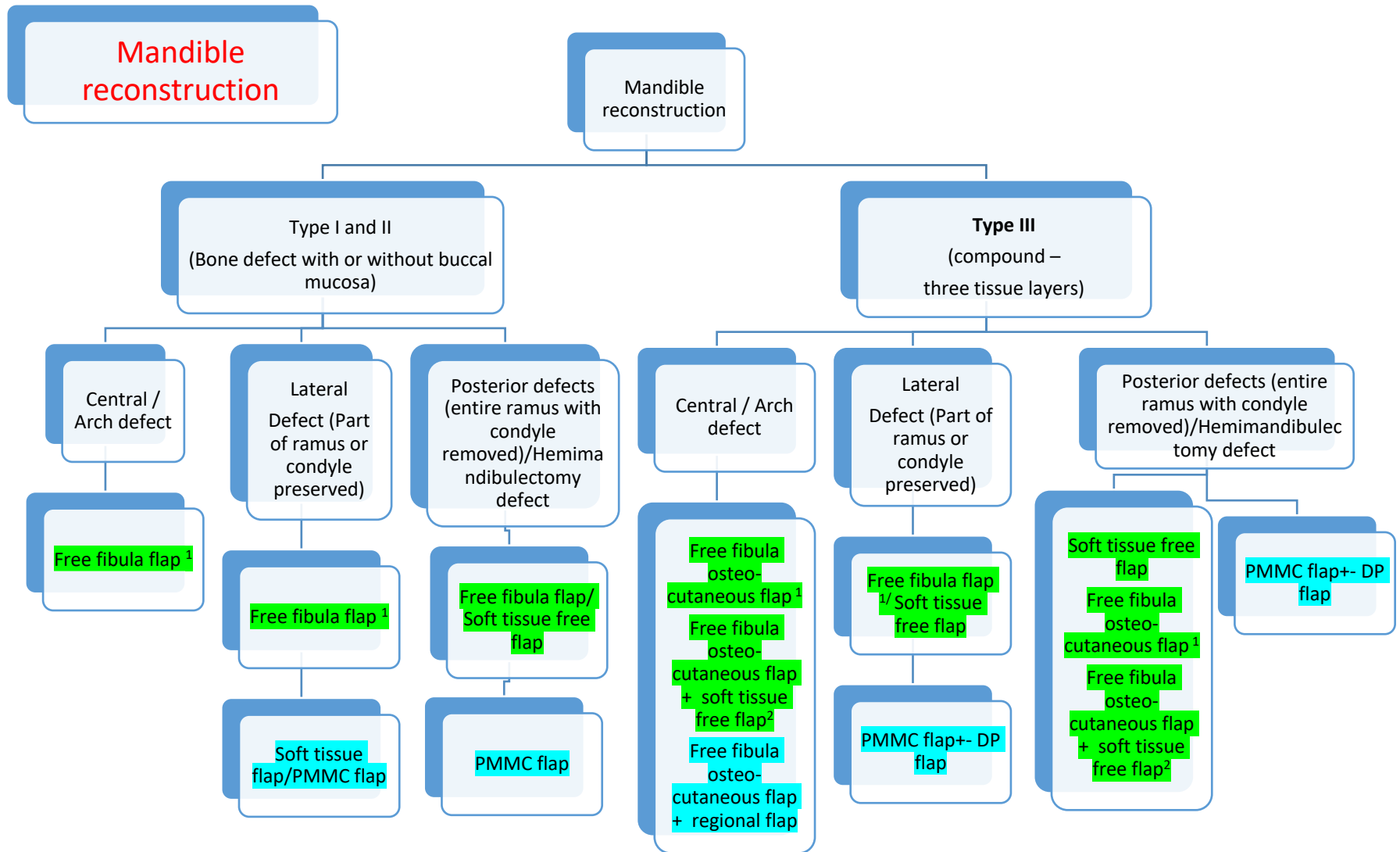
### References

1. Houston GC, Drew GS, Vazquez B, Given KS. The extended latissimus dorsi flap in repair of anterior abdominal wall defects. *PlastReconstr Surg.* 1988 Jun;81(6):917-24. doi: 10.1097/00006534-198806000-00015. PMID: 2967516.
2. Tamai M, Nagasao T, Miki T, Hamamoto Y, Kogure T, Tanaka Y. Rotation arc of pedicled anterolateral thigh flap for abdominal wall reconstruction: How far can it reach? *J PlastReconstrAesthet Surg.* 2015 Oct;68(10):1417-24. doi: 10.1016/j.bjps.2015.06.010. Epub 2015 Jun 25. PMID: 26188402.
3. Contedini F, Negosanti L, Pinto V, Tavaniello B, Fabbri E, Sgarzani R, Tassone D, Cipriani R. Tensor fascia latae perforator flap: An alternative reconstructive choice for anterolateral thigh flap when no sizable skin perforator is available. *Indian J Plast Surg.* 2013 Jan;46(1):55-8. doi: 10.4103/0970-0358.113707. PMID: 23960306; PMCID: PMC3745122.
4. Kimata Y, Uchiyama K, Sekido M, et al. Anterolateral thigh flap for abdominal wall reconstruction. *Plastic and Reconstructive Surgery.* 1999 Apr;103(4):1191-1197. DOI: 10.1097/00006534-199904040-00014. PMID: 1008850





- If long segmental loss of nerve or muscle compartment resection resulting in loss of function then tendon transfer, nerve transfer or functional muscle transfer can be considered
- STSG can be considered in instep area. Flap should be first choice in weight bearing areas
- Non vascularized bone graft may be used in defects < 6 cms in which bed vascularity is good. To be avoided if wound bed is infected/radiated or likely to receive radiation



- Green signifies best/preferred option, Blue signifies- resource based options, Red signifies salvage options

# National Cancer Grid

## Plastic & Reconstruction Guidelines 2024

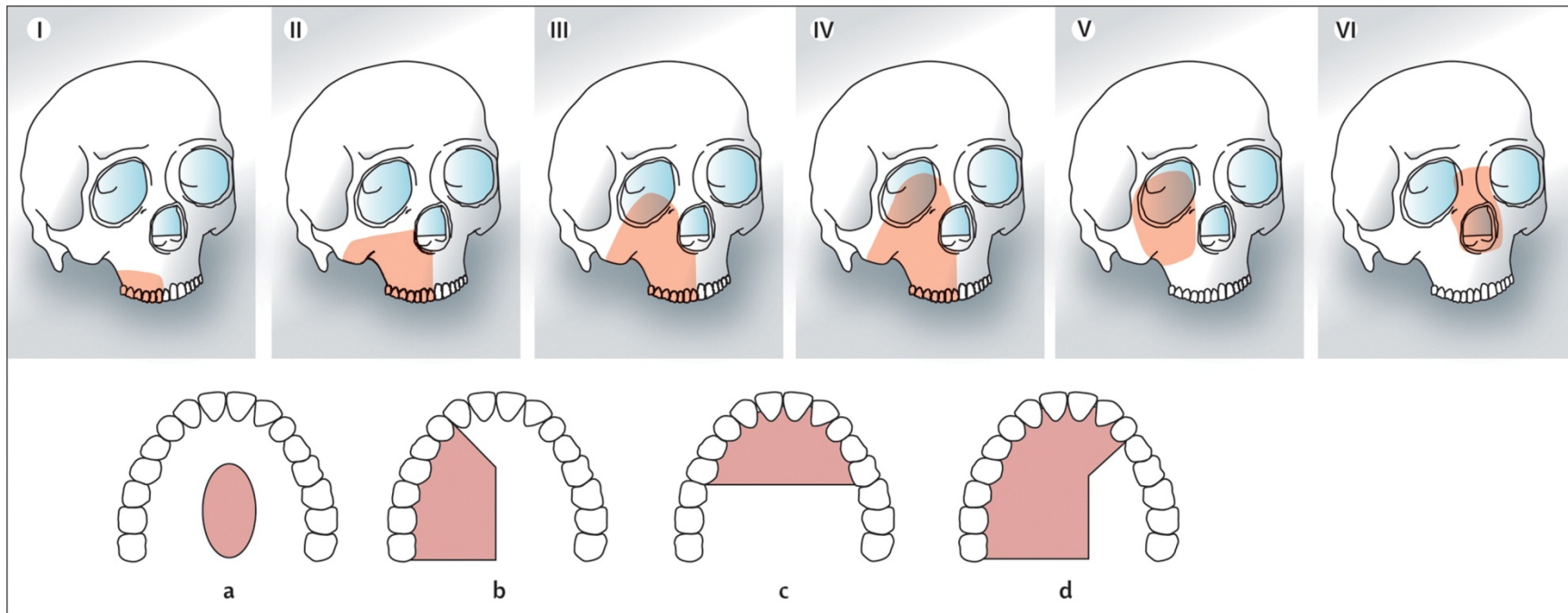
---

1. Free fibula osteocutaneous flap is first and preferred choice for bone reconstruction. Although depending upon surgeon's preference, donor site availability and defect, other bone flaps can also be an option such as
  - A) Free scapular parascapular flap
  - B) DCIA flap
2. If skin defect requirement is huge and one flap is not enough to provide the skin paddle, different combinations are possible such as two free flaps, or one free flap and one regional flap. In salvage situations plate with free flap or regional flaps is also an option.
3. Legends-
  - A) PMMC- Pectoralis major myocutaneous flap
  - B) DP flap- deltopectoral flap

### References:

1. Takushima, A., Harii, K., Asato, H., Momosawa, A., Okazaki, M., & Nakatsuka, T. (2005). Choice of osseous and osteocutaneous flaps for mandibular reconstruction. *International Journal of Clinical Oncology*, 10(4), 234–242.
2. Lavertu P, Wanamaker JR, Bold EL, Yetman RJ. The AO system for primary mandibular reconstruction. *Am J Surg* 1994; 168:503.
3. Kademani, D., Mardini, S., & Moran, S. (2008). Reconstruction of Head and Neck Defects: A Systematic Approach to Treatment. *Seminars in Plastic Surgery*, 22(03), 141–155.
4. Sharma, Shobhit, & Sudipta Bera. "Oromandibular reconstruction with free fibula osteocutaneous flap after oncologic resection: retrospective analysis of surgical experience and operative outcome of 56 cases." *International Surgery Journal [Online]*, 6.10 (2019): 3674-3680
5. Goh, B. T., Lee, S., Tideman, H., & Stoelinga, P. J. W. (2008). Mandibular reconstruction in adults: a review. *International Journal of Oral and Maxillofacial Surgery*, 37(7), 597–605.
6. Wei FC, Celik N, Chen HC, Cheng MH, Huang WC. Combined anterolateral thigh flap and vascularized fibula osteoseptocutaneous flap in reconstruction of extensive composite mandibular defects. *Plast Reconstr Surg*. 2002 Jan;109(1):45-52.
7. Chung JH, Kim DS, Yoon ES. Reconstruction of Extensive Oromandibular Defect With Simultaneous Dual Free Flap Transfer. *J Craniofac Surg*. 2022 May 1;33(3):867-869.
8. Gibber MJ, Clain JB, Jacobson AS, et al. Subscapular system of flaps: an 8-year experience with 105 patients. *Head Neck* 2015;37:1200-6.
9. Bansal AP, Buchakjian MR. Subscapular system free flaps for oromandibular reconstruction. *Plast Aesthet Res* 2021;8:59.
10. Boyd JB, Mulholland RS, Davidson J, Gullane PJ, Rotstein LE, Brown DH, Freeman JE, Irish JC. The free flap and plate in oromandibular reconstruction: long-term review and indications. *Plast Reconstr Surg*. 1995 May;95(6):1018-28.
11. Yadav, Prabha & Ahmad, Quazi & Shankhdhar, Vinay Kant & Nambi, G.I.. (2012). Reconstruction of oncological oro-mandibular defects with double skin paddled-free fibula flap: A prudent alternative to double flaps in resource-constrained centres. *Journal of cancer research and therapeutics*. 8. 91-5. 10.4103/0973-1482.95181.

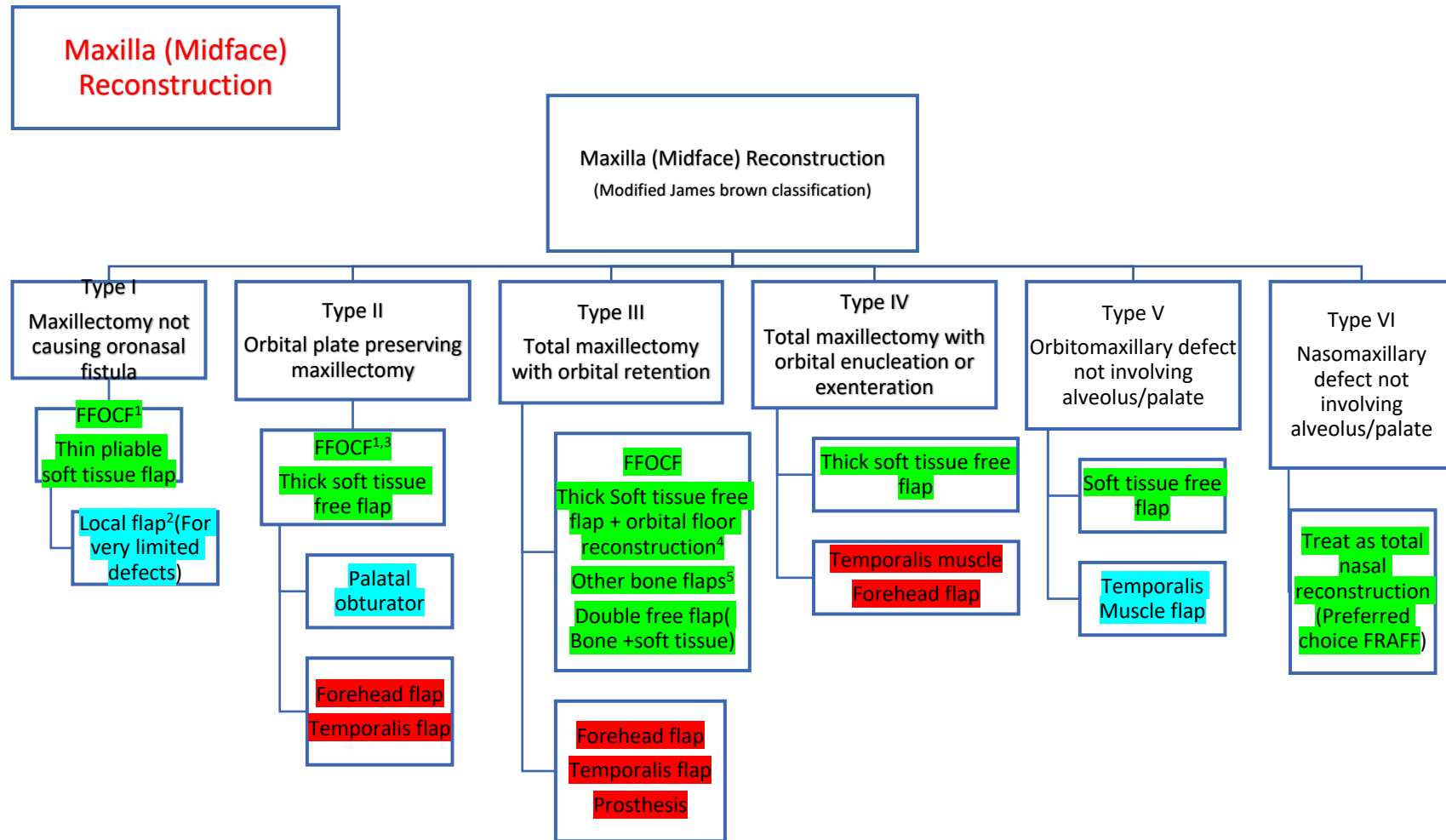
Revised James Brown classification-



Classification of vertical and horizontal maxillectomy and midface defect

Vertical classification: I—maxillectomy not causing an oronasal fistula; II—not involving the orbit; III—involving the orbital adnexae with orbital retention; IV—with orbital enucleation or exenteration; V—orbitomaxillary defect; VI—nasomaxillary defect. Horizontal classification: a—palatal defect only, not involving the dental alveolus; b—less than or equal to 1/2 unilateral; c—less than or equal to 1/2 bilateral or transverse anterior; d—greater than 1/2 maxillectomy. Letters refer to the increasing complexity of the dentoalveolar and palatal defect, and qualify the vertical dimension.

Reference- Brown JS, Shaw RJ. Reconstruction of the maxilla and midface: introducing a new classification. *Lancet Oncol.* 2010 Oct;11(10):1001-8. doi: 10.1016/S1470-2045(10)70113-3. PMID: 20932492



- Green signifies best/preferred option, Blue signifies- resource based options, Red signifies salvage options



# National Cancer Grid

## Plastic & Reconstruction Guidelines 2024

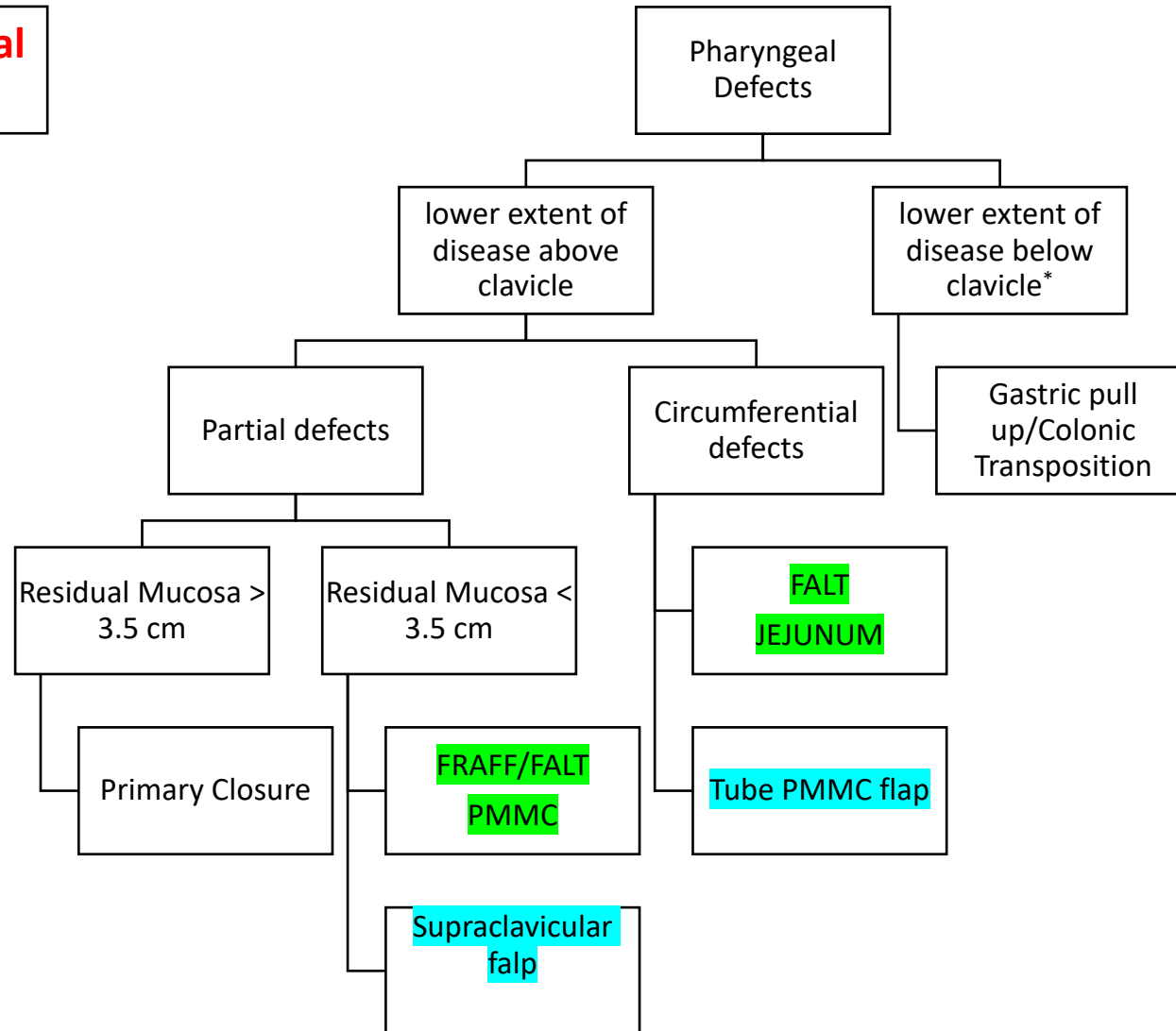
---

1. When defect is crossing midline, FFOCF is preferred over soft tissue flaps
2. If defect is posterior to canine, soft tissue flap is preferred
3. Local flap options – Nasolabial, palatal flap, temporalis flap
4. Other bone flaps can also be considered depending on surgeon preference- eg DCIA flap, Scapular flap
5. Options for orbital floor reconstruction- Non vascularized bone graft (Autograft), Titanium mesh etc

### Legends-

1. FFOCF- free fibula osteocutaneous flap
2. FRAFF- free radial artery forearm flap

**Pharyngeal Defects**



- Green signifies best/preferred option, Blue signifies- resource based options, Red signifies salvage options

### References:

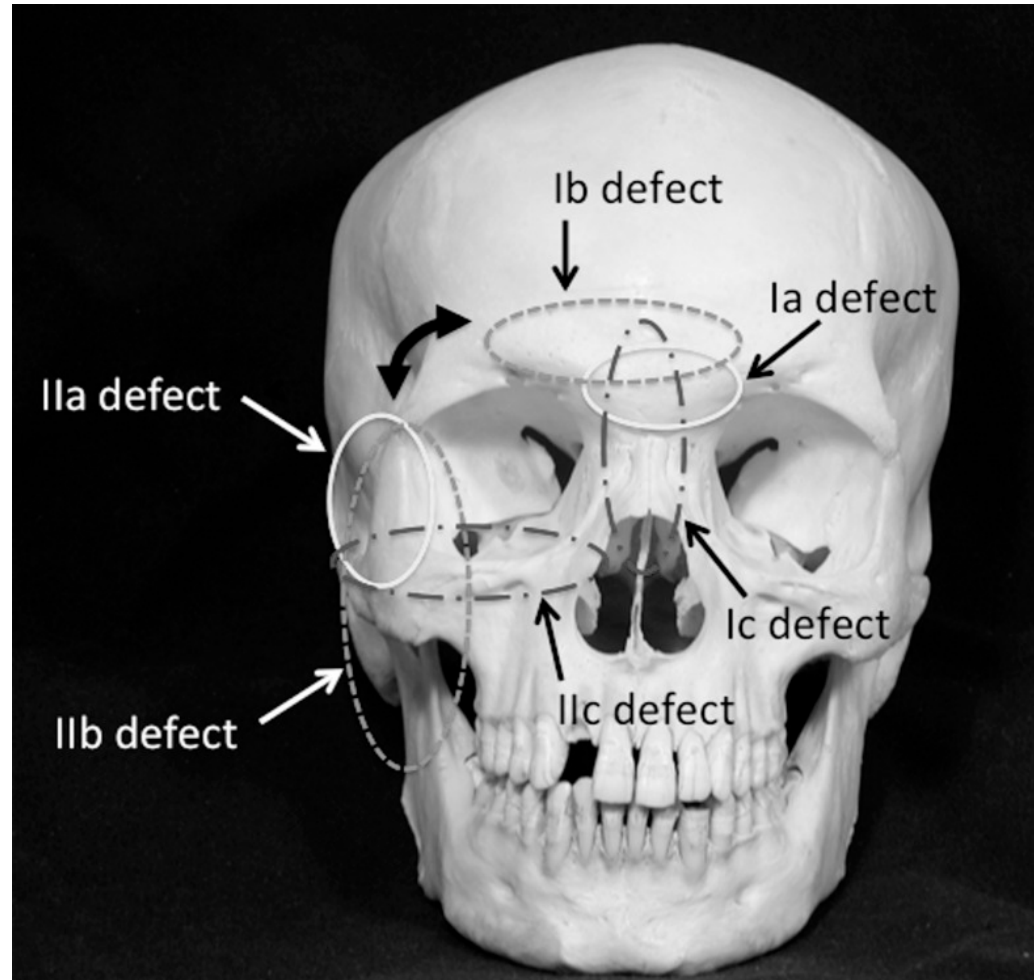
1. Yabe, T. , Ashford, B. . Reconstruction of Pharyngeal Defects. In: Sun, H. (. , editor. Surgical Management of Head and Neck Pathologies [Internet]. London: IntechOpen; 2020 [cited 2022 Nov 11]. Available from: <https://www.intechopen.com/chapters/73654> doi: 10.5772/intechopen.94191
2. Yu, P., Hanasono, M.M., Skoracki, R.J., Baumann, D.P., Lewin, J.S., Weber, R.S. and Robb, G.L. (2010), Pharyngoesophageal reconstruction with the anterolateral thigh flap after total laryngopharyngectomy. *Cancer*, 116: 1718-1724.
3. Denewer, A., Khater, A., Hafez, M.T. *et al.* Pharyngoesophageal reconstruction after resection of hypopharyngeal carcinoma: a new algorithm after analysis of 142 cases. *World J SurgOnc***12**, 182 (2014).
4. Balasubramanian D, Subramaniam N, Rathod P, Murthy S, Sharma M, Mathew J, et al. Outcomes following pharyngeal reconstruction in total laryngectomy – institutional experience and review of the literature. *Indian J PlastSurg* 2018;51:190-5.
5. Raghbir M, Brown JS, Mehanna H. Reconstructive considerations in head and neck surgical oncology: United Kingdom national multidisciplinary guidelines. *The Journal of Laryngology & Otology* (2016), 130 (Suppl. S2), S191–S197.

### Legends-

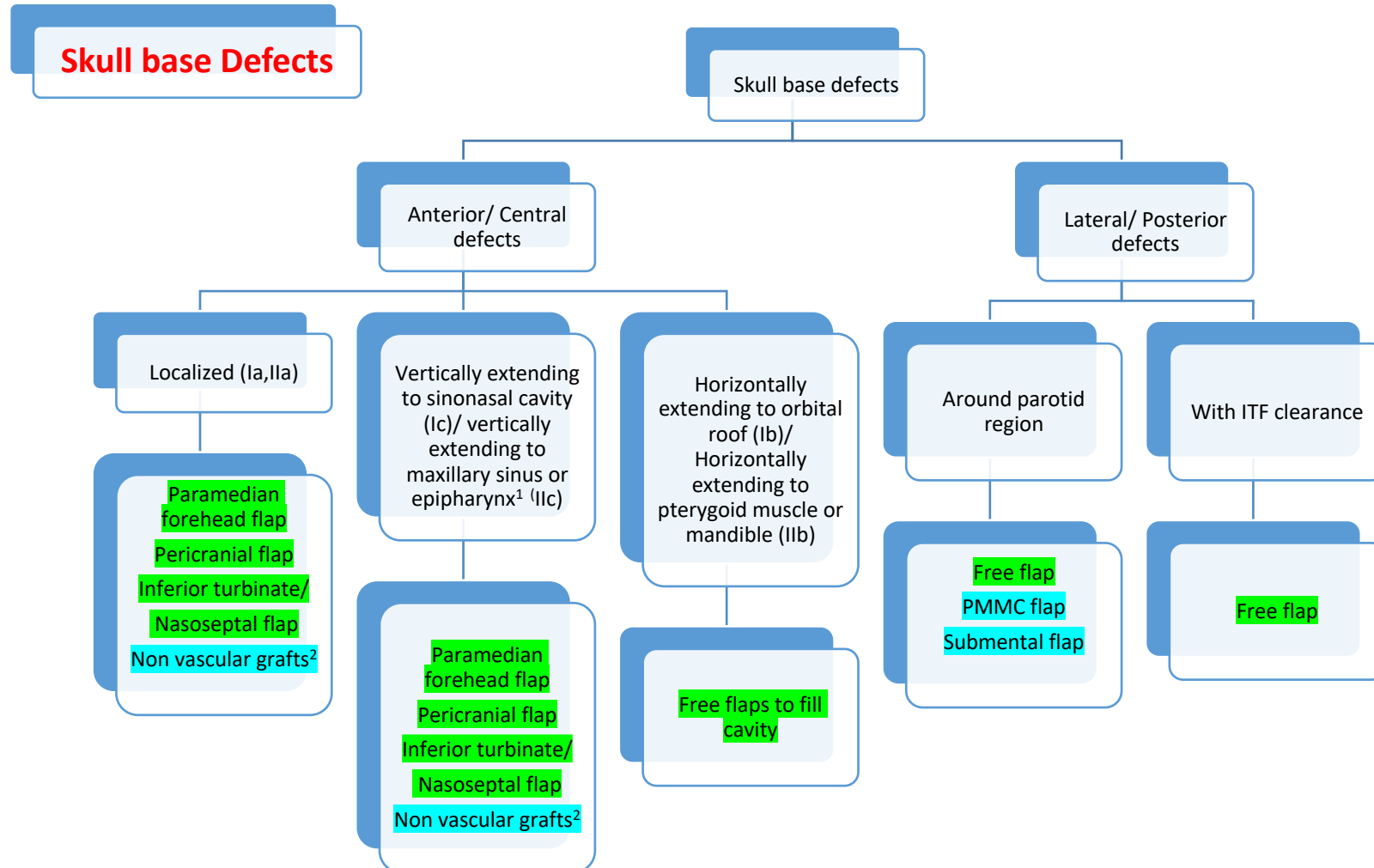
FALT- Free anterolateral thigh flap

PMMC- Pectoralis Major myocutaneous flap

Classification:



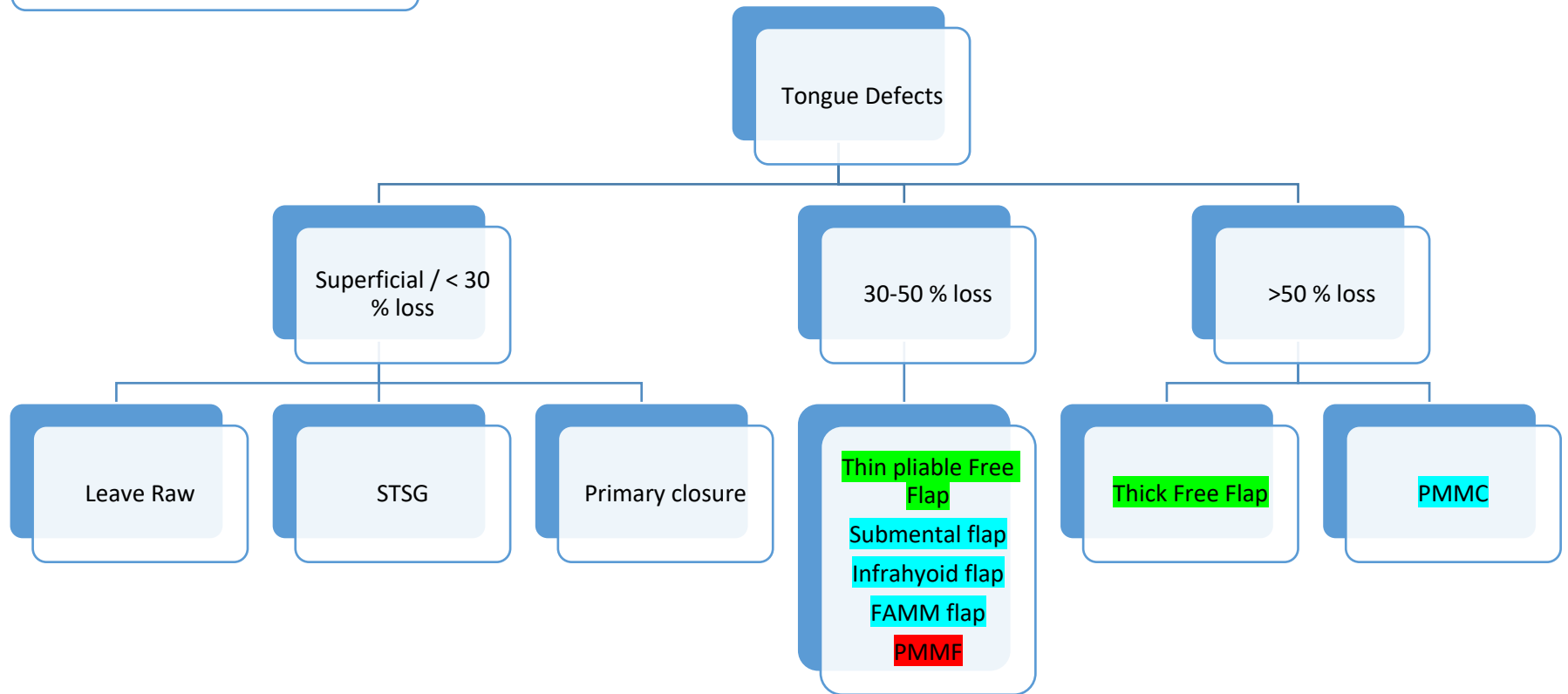
Yano T, Okazaki M, Tanaka K, Iida H, Aoyagi M, Tsunoda A, Kishimoto S. A new concept for classifying skull base defects for reconstructive surgery. *J Neurosurg B Skull Base*. 2012 Apr;73(2):125-31. doi: 10.1055/s-0032-1301402. PMID: 23543797; PMCID: PMC3424621



1. Defects involving orbital contents or skin involvement, free flap is the preferred reconstructive choice

2. Non vascularized grafts should be avoided if post operative radiation is anticipated

## Tongue Defects



# National Cancer Grid

## Plastic & Reconstruction Guidelines 2024

---

- Green signifies best/preferred option, Blue signifies- resource based options, Red signifies salvage options

### References:

1. Vincent, Aurora et al. "Free-Flap Reconstruction of the Tongue." *Seminars in plastic surgery* vol. 33,1 (2019): 38-45. doi:10.1055/s-0039-1677789
2. Hsiao, H. T., Leu, Y. S., & Lin, C. C. (2003). Tongue reconstruction with free radial forearm flap after hemiglossectomy: a functional assessment. *Journal of reconstructive microsurgery*, 19(3), 137–142. <https://doi.org/10.1055/s-2003-39824>
3. Chang, E.I., Yu, P., Skoracki, R.J. et al. Comprehensive Analysis of Functional Outcomes and Survival After Microvascular Reconstruction of Glossectomy Defects. *Ann SurgOncol* 22, 3061–3069 (2015). <https://doi.org/10.1245/s10434-015-4386-6>
4. Gangiti, K. K., Gondi, J. T., Nemade, H., Sampathirao, L. M., Raju, K. V., & Rao, T. S. (2016). Modified pectoralis major myocutaneous flap for the total glossectomy defects: Effect on quality of life. *Journal of surgical oncology*, 114(1), 32–35. <https://doi.org/10.1002/jso.24260>
5. Daar DA, Abdou SA, Cohen JM, Wilson SC, Levine JP. Is the Medial Sural Artery Perforator Flap a New Workhorse Flap? A Systematic Review and Meta-Analysis. *PlastReconstr Surg*. 2019;143(2):393e-403e. doi:10.1097/PRS.0000000000005204

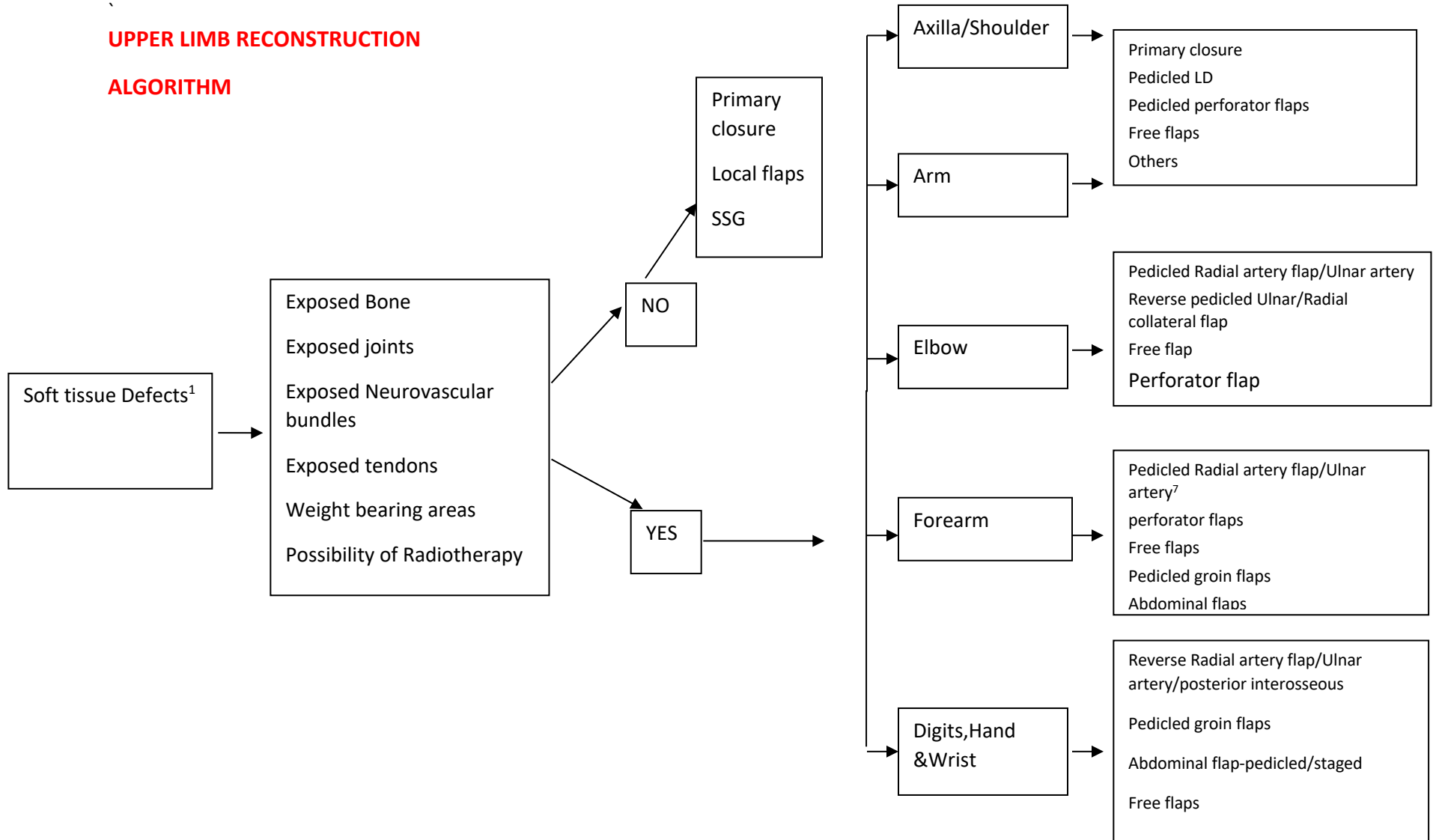
### Legends

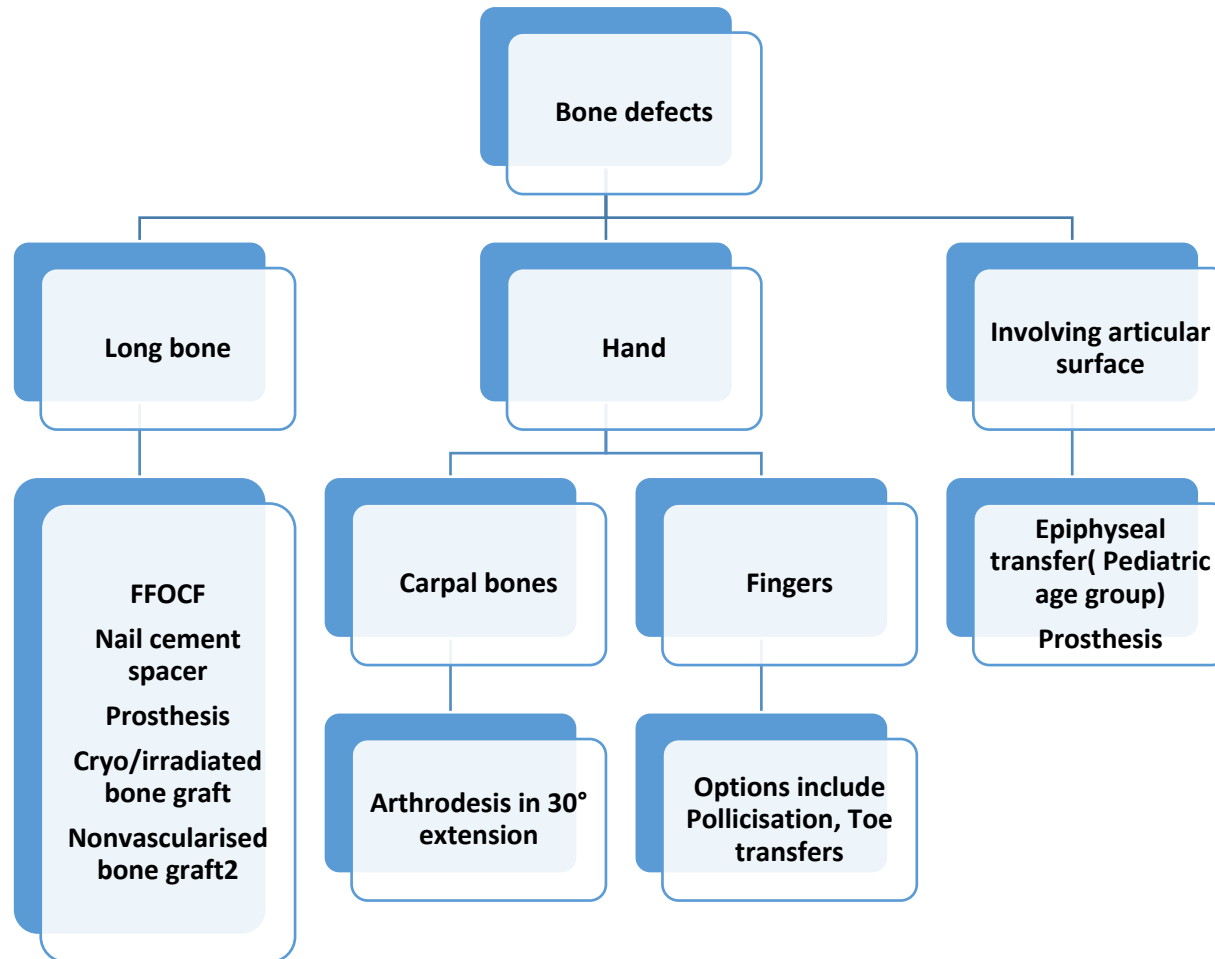
- STSG- Split thickness skin graft
- FAMM- Facial artery myomucosal flap
- PMMF- pectoralis major muscle flap
- PMMC- pectoralis major myocutaneous flap



**UPPER LIMB RECONSTRUCTION**

**ALGORITHM**





If long segmental loss of nerve or muscle compartment resection resulting in loss of function then tendon transfer, nerve transfer or functional muscle transfer can be considered

Non-vascularized bone graft may be used in defects < 6 cms in which bed vascularity is good. To be avoided if wound bed is infected/radiated or likely to receive radiation